

Standards and Quality Committee

# Photography and Documentation

Standards for Recovered Organs



**ASTS**  
American Society of  
Transplant Surgeons

# Table of Contents

<b>General Recommendations</b>	1
<b>Organ-Specific Recommendations</b>	2
<b>Photography Examples</b>	3
Liver Examples	5
Kidney Examples	6
Pancreas Examples	8

## Purpose

With changing abdominal organ allocation schemes in the United States, more organs are being procured distant to the transplant center by surgeons not known to the accepting transplant center. Many organs, particularly high KDPI kidneys and extended criteria livers, are frequently difficult to place and may have a high rate of discard. Further anatomic information in the form of photographs may facilitate surgeon confidence to accept risky organs that may have unknown or uncertain attributes.

In renal transplantation, lack of clarity surrounding anatomy may contribute to organ declines, especially late declines after the organ has shipped (when anatomy is worse than expected). Lack of clarity in renal transplantation includes minimal details regarding arterial plaque or other abnormalities, lack of detailed anatomy sheets, and lack of clear imaging. Smaller, rural, and lower resource programs may have more difficulty accepting marginal organs without good documentation, which may increase disparities in access. In liver transplantation, good pictures of the flushed liver allow for improved timing of the recipient hepatectomy.

Improving the quality of images at the time of procurement should improve and facilitate organ acceptance and utilization. This committee recommends increased attention to detail for anatomy documentation and guidelines for photographic/video documentation of procured abdominal organs. Example photos are provided.

---

## Scope

Recommendations will include donor abdominal organs. Liver acceptance during local recovery is a dynamic process that is initiated at the time of organ visualization and as such we recommend real time communication of imaging from the operating room between the donor and recipient surgeon. This liver imaging usually serves as a confirmation of the report. In contrast, the frequent delay in kidney allocation creates a need for imaging to be uploaded into UNET rapidly and with increased detail. OPO support and participation in this project will facilitate implementation and success of the recommendations. Additionally, we recommend an update to anatomy sheets for all kidney procurements, detailed below.

### • **General Recommendations:**

- All pictures should meet OPTN and local OPO standards including labels with UNOS ID and organ type and laterality for each picture.
- Procuring surgeons should take note of the concerns they would have if accepting an organ and help drive the detailed documentation. Procuring surgeons are encouraged to review images with OPO staff before scrubbing out of a procurement.
- **Abnormalities or crucial anatomy:** Any abnormality and/or key anatomy (vessels, bifurcations) should be identified in the anatomy sheet and have a corresponding image.
  - An update in OPO/UNET anatomy sheets for kidneys could improve the common issue of arterial plaque. Anatomy sheets do not usually provide how deep plaque extends or how much of the circumference of the artery is involved. Significant clarity would be provided by adding a space on anatomy sheets underneath the line “arterial plaque” and “soft/hard” to describe the “distance from orifice” and “% circumference”.
  - All abnormalities or aberrant anatomy should have a picture and documentation to include specific measurements or details helpful to an accepting surgeon.

- All abnormalities or aberrant anatomy should have a picture and documentation to include specific measurements or details helpful to an accepting surgeon.
      - Without depth, extent, size of plaque or damage, it is difficult to assess remotely.
    - Utilization of rulers and pointers (forceps) to indicate areas of concern can be highly beneficial.
  - **Resolution, Zoom, and Focus:** High resolution is important for detailed images.
    - Use the highest resolution setting available on the camera. Most modern smartphones have sufficient pixel count for detailed images. A minimum of 12 megapixels is recommended. Recognize the constraints of the smartphone's optical zoom and avoid using high digital zoom levels, which can degrade the image quality. Limit digital zoom to a maximum of 4X to balance the need for detail with the necessity to maintain image clarity. When closer details are required, and optical zoom is not sufficient, it is preferable to take the highest resolution image possible from a safe distance and then crop the image later, ensuring that the essential details are still visible without significant pixelation. This approach helps maintain the integrity of the sterile field while still providing usable images for medical evaluation.
    - Use the tap-to-focus feature on the smartphone to ensure the organ is in sharp focus.
    - If the smartphone has a macro mode, use it for close-up shots of specific abnormalities or areas of interest.
    - Do not use filters.
  - **Lighting Considerations:** Good lighting is crucial. Avoid direct overhead lights to reduce glare. Natural light or well-diffused artificial light can provide clear and evenly lit images. If using artificial light, position it to minimize shadows and glare on the organ. Shadows must be avoided. Obviously, clear imaging without blurring or glares is required. Sometimes, moving overhead lights off of the organ helps reduce glare. See examples for the effect of lighting on images.
  - **Background:** Use a neutral, non-reflective background. This ensures the focus remains on the organ without any distractions.
  - **Size reference:** Include a ruler or other standard object for size reference.
  - **Editing:** Minimal editing should be done to maintain the authenticity of the image. Adjustments for brightness and contrast might be necessary but should be kept to a minimum.
  - **File Format and Sharing:** Save images in a widely compatible format such as JPEG or PNG. Ensure that the method of sharing these images complies with patient confidentiality and data protection laws.
- **Organ Specific Recommendations**
  - **Liver:** The following pictures should be taken for liver evaluation:
    - **Pre-cross clamp:** Initial picture upon full abdominal exposure with a ruler measuring the left and right lobe.
      - If there is a particular concern of size matching a right lobe A-P (Depth) picture can be helpful.
      - Short videoclip to demonstrate texture/turgor of the liver.
    - **Post cross-clamp:** obtain at least 2 pictures on the backtable, including the anterior and posterior surface of the liver, arterial patch, length of portal vein, length of supra-hepatic IVC.

- o Any laceration, hematoma or other lesions should be documented on the picture.

- o **Kidneys**

- At least 2 images for all kidneys
  - o Show both anterior and posterior surfaces of kidney
    - Fat should be cleaned to show at least 30-50% of the parenchyma surface (unless damage will be caused, then noted in anatomy sheet)
    - Biopsy site should be visible
  - o Include aortic cuff and renal vein/IVC in picture
    - Appropriate imaging of vasculature often requires additional closeup picture
  - o Include ureter in a picture
  - o Include biopsy site in a picture
- Additional close-up images with ruler should be provided in the case of the following issues:
  - o Vascular Issues:
    - Documentation should accompany the picture (on the anatomy sheet). More detail on the documentation of plaque can facilitate success of allocation as well as prevent discards.
      - o **Arterial plaque:** document the following:
        - depth of extension from the orifice (distance from orifice to resolution of plaque)
        - the percent of arterial circumference involved with plaque (50% circumference) and whether lumen is narrowed
        - quality of plaque (soft, hard, ulcerated)
          - Example: arterial plaque should have an explanation of the texture (example soft/hard/ulcerated) but **also the depth and an approximation of the circumference** (example: soft plaque in 30% of the circumference extending 5mm from the orifice or cuff)
      - o Multiple arteries
        - Diameter and distance apart
        - Cuff and orifice for each
      - o **Cuts or tears** in artery or vein should be noted with following details:
        - Size and depth of tear
        - If repair attempted, a picture should be included
    - o Parenchymal issues (capsular tear, hematoma, petechiae, mass)
      - Note size and location
    - o Ureteral damage
      - Note distance from hilum
    - o Consideration for pediatric en bloc grafts
      - Provide close-up images to illustrate the distance between the upper edges of the aorta/IVC and the renal vessels. Additionally, capture the distal edges of

the aorta/IVC to clearly show whether the aortic bifurcation is included or excluded.

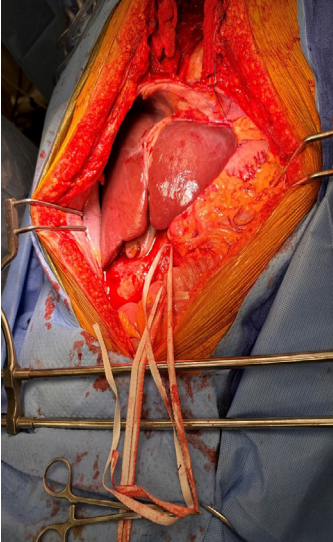
- Provide measurements on anatomy sheet of the vessel size
- o **Pancreas:** Although some centers will send their own surgeon for pancreas recovery, transplant surgeons sometimes heavily rely on pictures/videos for assessment of organ before acceptance. Pictures and/or videos play a significant role in final placement of pancreas allograft and a standardize approach can help in minimizing discards.
  - Pictures of pancreas allograft before and after cross clamp (when organ is recovered)
  - Provide at least 2 pictures of pancreas allograft after cross clamp (anterior and posterior surface) including (duodenum, pancreas, and spleen)
  - Special attention should be paid to obtain pictures of following vital structures.
    - o Portal vein – to show length and diameter (include measurement on anatomy sheet).
    - o Arterial stumps – SMA and Splenic artery (with prolene suture)
    - o Tail of pancreas – to assess if there is any traction injury.
    - o Root of mesentery
    - o Picture of iliac Y-graft conduit including documentation that there is no crotch injury
    - o Any potential parenchymal injury
- o **Intestines:** Photography standards are outside the scope of this document because intestines are almost universally recovered by the accepting center, or a surgeon well known to the recipient surgeon.

# Photography Examples

---

## Example Liver Photos:

***In-situ Liver Pictures:*** Note full view of liver with multiple standard objects for size reference and excellent lighting with minimal glare.

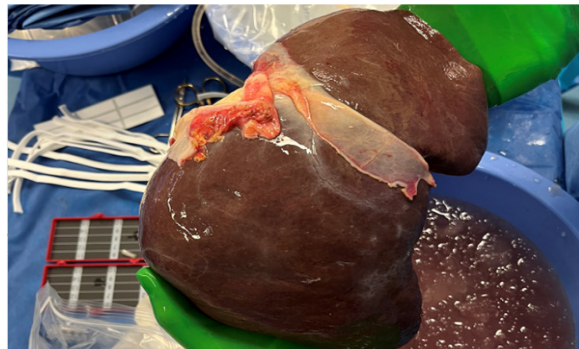


**Figure 1**

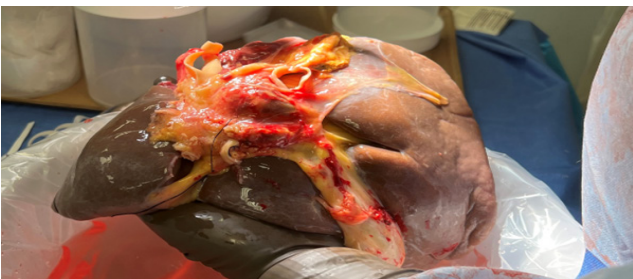***Backtable Liver Anatomy:*** In figures 2 and 3, note that the ruler provides detailed size. This is the most preferable. In the second pair, note that background instruments and glove size visible provide reference for size. A combination of 2 pictures provides anterior and posterior views with vessels/detailed anatomy. Some minimal shadow is evident on the pictures, but it does not inhibit viewing of color and contour.



**Figure 2**



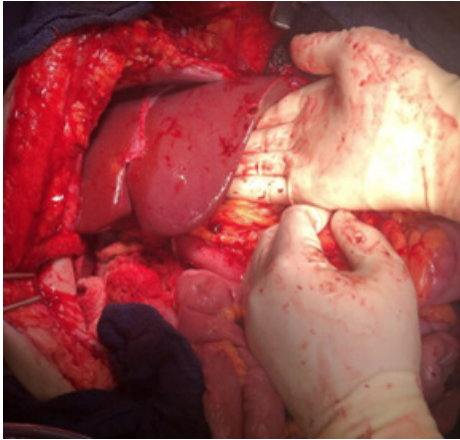
**Figure 3**



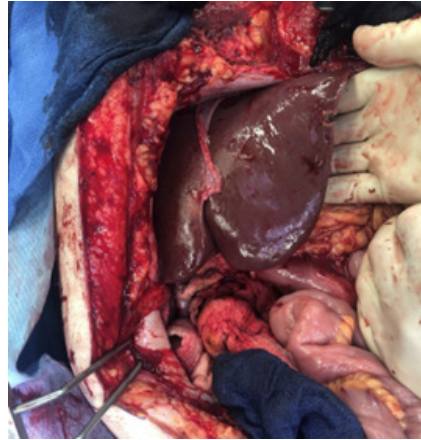
**Figure 4**



**Lighting Effects on Pictures:** The following 2 pictures are identical except lighting. Note the difference.



**Figure 5**



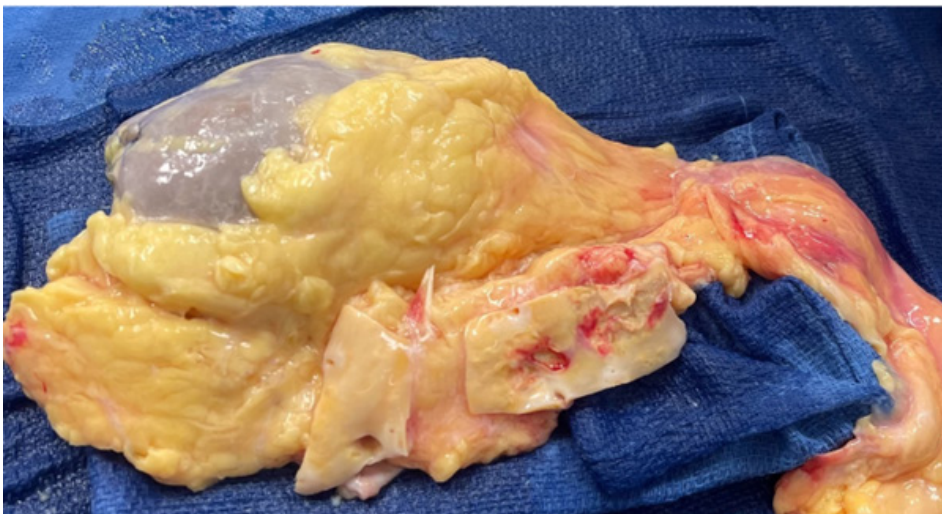
**Figure 6**

For NRP cases: in-situ photos of the liver immediately after initiation of NRP and towards the end (prior to cross clamp) should be uploaded to DonorNet.

---

### **Example Kidney Photos:**

**Backtable Anterior and Posterior with ruler and appropriate labels:** Below is an excellent view of artery orifice and plaque.



**Figure 7**

The following are good photographs but could use improvements. Figure 8 shows a vein but does NOT give sufficient view of the artery. Moving the ruler to the side of the vein would have been helpful in this picture. Again, the second picture does NOT fully show the aortic cuff, but it is revealed in the third picture showing the damage. The anatomy sheet should correlate with the damage and level of plaque. Note that the perfusion cannula is inhibiting the view of the cuff and artery. An additional picture should be provided.

Figure 11 shows excellent exposure of the aortic cuff of the renal artery.



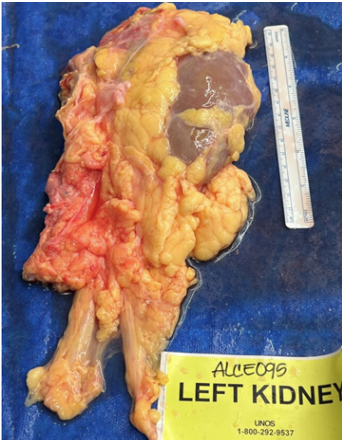


Figure 8

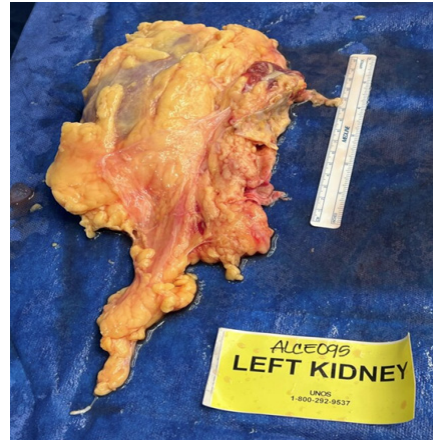


Figure 9

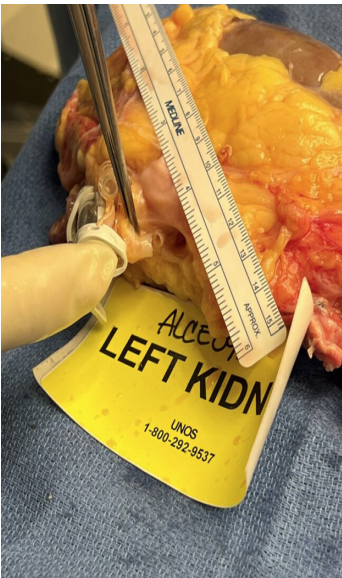


Figure 10

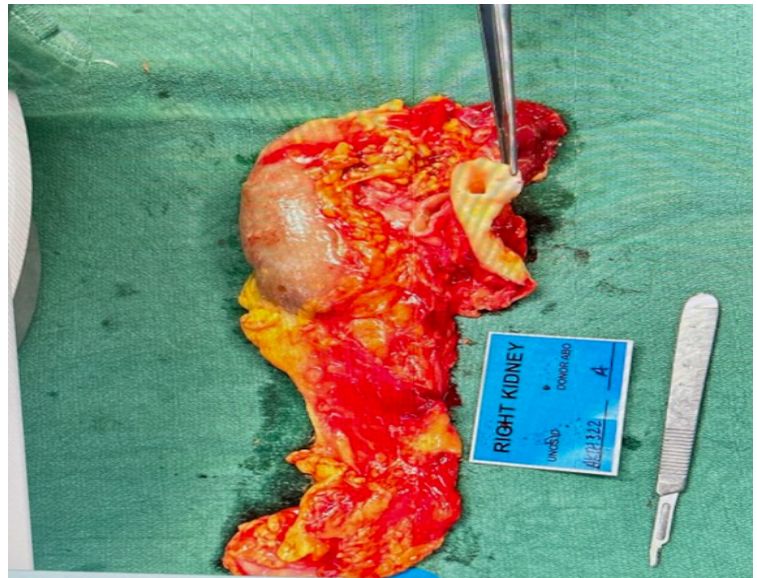


Figure 11

**Example En-bloc Kidneys:** Aortic anatomy is clearly shown with reference from a forceps. However, a ruler should be in place.

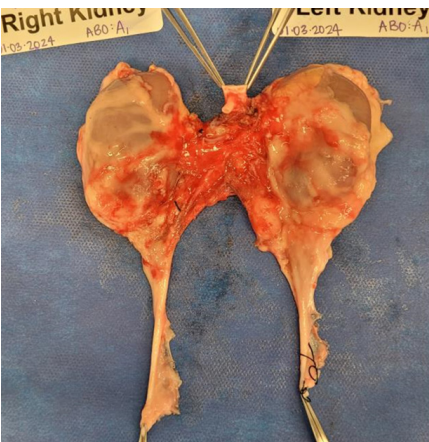
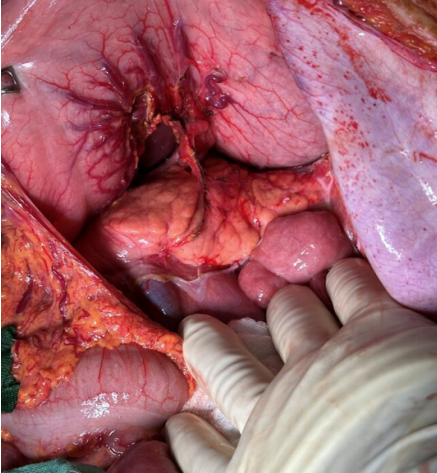


Figure 12

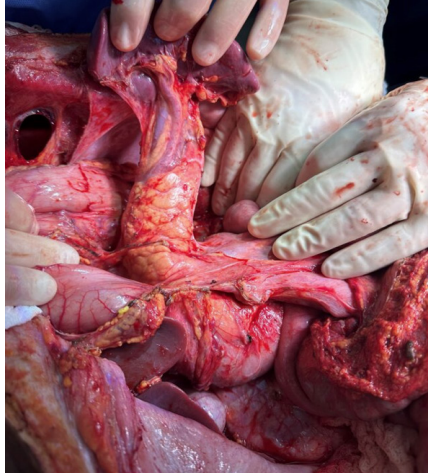---

## Example Pancreas Photos:

***In situ Pancreas:*** Figure 13 shows in situ anatomy and quality of the pancreas. Figure 14 is very helpful to show the tail of the pancreas and spleen with or without damage.

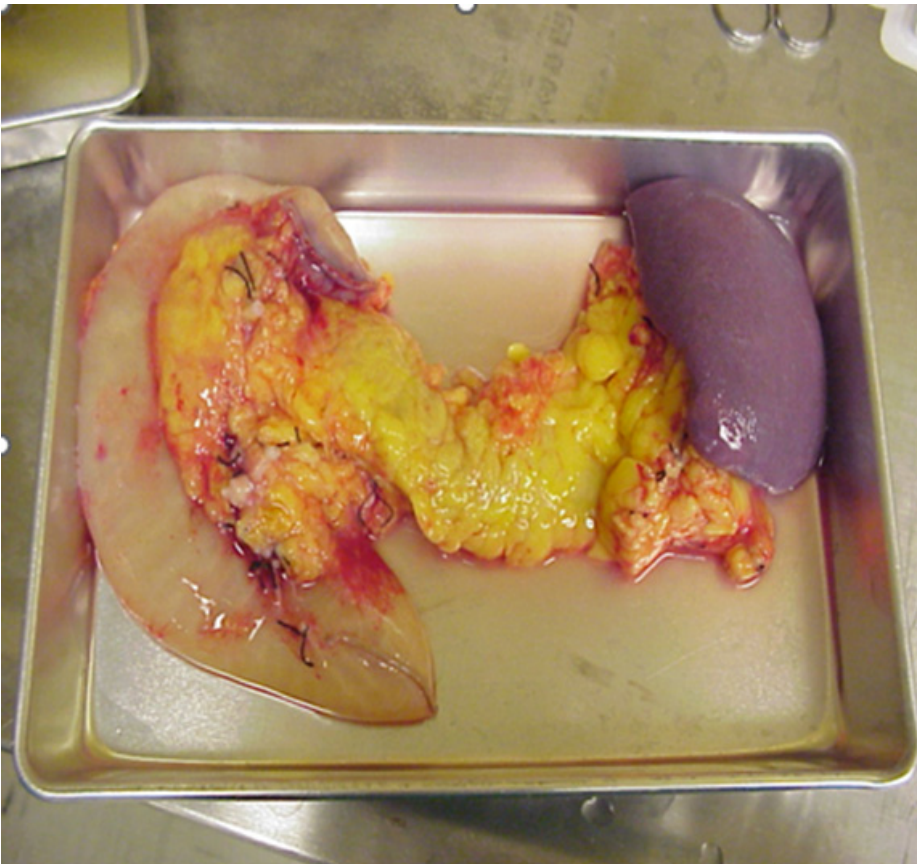

**Figure 13**



**Figure 14**

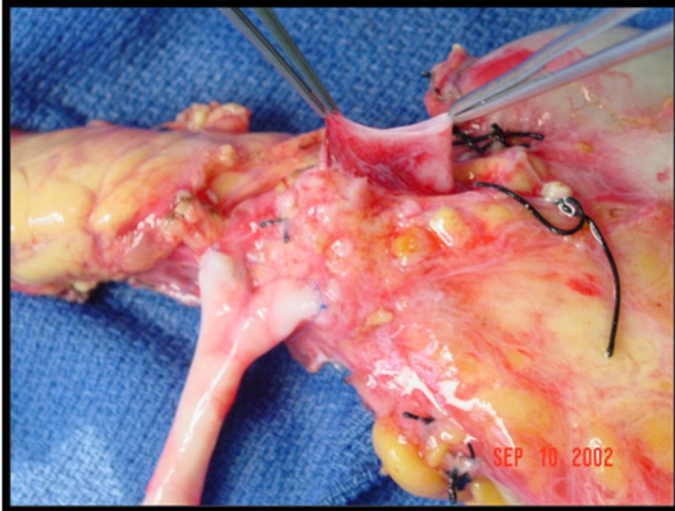
***Provide at least 2 pictures of pancreas allograft after cross clamp*** (anterior and posterior surface) including (duodenum, pancreas, and spleen). Figure 15 gives a good overview but needs a ruler as well as closeup of vascular structures.



**Figure 15**



Special attention should be paid to obtain pictures of following vital structures. The following pictures are after backtable, so not what would be provided at the time of a procurement. However, the pictures demonstrate the necessary attention to detail for the body of pancreas and vascular structures.



**Figure 16**

*Acknowledgements: The ASTS Council acknowledges members of the 2023 – 2024 and 2024 – 2025 members of the Standards & Quality Committee who contributed to this document. An additional acknowledgement to Satish Nadig MD, PhD, for his photo contributions.*

*Ramesh Batra, MBBS, MRCS, FRCS*

*Johanna Bayer, MD*

*Lynsey Biondi, MD*

*Humberto Bohorquez, MD*

*Zachary Dietch, MD, MBA*

*Samer Ebaid, MD, PhD, FACS*

*James Guarrera, MD*

*Reagan Huber, PA-C*

*Marwan Kazimi, MD*

*Daniela Ladner, MD, MPH*

*David Levi, MD*

*Matt Levine, MD, PhD*

*Martin Montenovolo, MD, FACS*

*Omair Nadeem*

*Ahmed Nassar, MD*

*Muhammad Saeed, MD*

*Junichiro Sageshima, MD*

*Tim Schmitt, MD*

*Alvin Wee, MD*